

Lamellar Keratoplasty

Michael Duplessie, MD

The concept of creating a deep lamellar bed for lamellar keratoplasty is not new. Mühlbauer was the first to describe a technique for anterior lamellar keratoplasty (ALK) in 1840.¹ Penetrating keratoplasty (PKP) has long been the standard treatment for severe corneal pathology. Lamellar surgery has endured significant technical challenges since its inception. The posterior corneal surface is invisible through an operating microscope, due to the small difference in the refractive index between corneal tissue and aqueous humor. Exposing Descemet's membrane in lamellar surgery is a painstaking procedure. Diamond blades and micrometers have lessened, but not eliminated, inadvertent perforations.

Recent advances in surgical equipment and technique have redefined lamellar corneal surgery. Viscosurgical, microkeratome, and laser advances have improved the ability to expose Descemet's membrane, and have dramatically reduced surgery time, while improving the safety of the procedure. There is great promise that they will reduce the optical distortion and decreased best-corrected visual acuity.² The ability to remove corneal pathology, add structural support, and decrease the risk of an immune-mediated graft reaction has caused an upsurge in lamellar keratoplasties.¹

There are 2 types of lamellar keratoplasty: anterior and posterior. ALK does not include corneal endothelium, so donor tissue is more easily obtained. This technique enables surgeons to use corneal grafts with low endothelial density. In a recent eye bank study, deep lamellar keratoplasty (DLK) represented 29.8% (85 out of 285) of corneal transplantations. The ability to use previously unsuitable corneas with poor endothelial function permitted a 24.5% increase in corneal grafting in a study by Muraine and colleagues.³

The decreased risk of allograft reaction permits a shorter course of postoperative topical steroid and attendant complications. The anterior stroma is incised using a trephine that can be set to a depth not exceeding the corneal thickness, and stromal layers may be dissected until the desired depth is obtained. Indications include anterior corneal pathology in which the posterior cornea is unaffected. The indications for deep ALK have expanded from keratoconus and hereditary dystrophies (Figure 14-1) to include severe ocular surface disease and cases following infection (Figure 14-2) and corneal perforation.

Posterior lamellar keratoplasty was developed because it is believed that by preserving the anterior corneal surface, there will be an overall reduction in refractive error and irregular astigmatism.⁴ This is especially effective for patients suffering from Fuchs dystrophy (Figure 14-3). Bullous keratopathy is the only absolute contraindication.

Anterior Lamellar Keratoplasty

ALK involves dissection of the host cornea to the level of deep stroma, followed by transplantation of donor corneal tissue without Descemet's membrane and endothelium. The indications for the use of anterior lamellar surgery has changed as the technology of the instrumentation has improved, and include keratoconus, laser in situ keratomileusis (LASIK)-induced kerectasia, corneal alkali burns, Terrien's marginal degeneration, anterior corneal dystrophies (Figure 14-2), and corneconjunctival malignant melanoma.

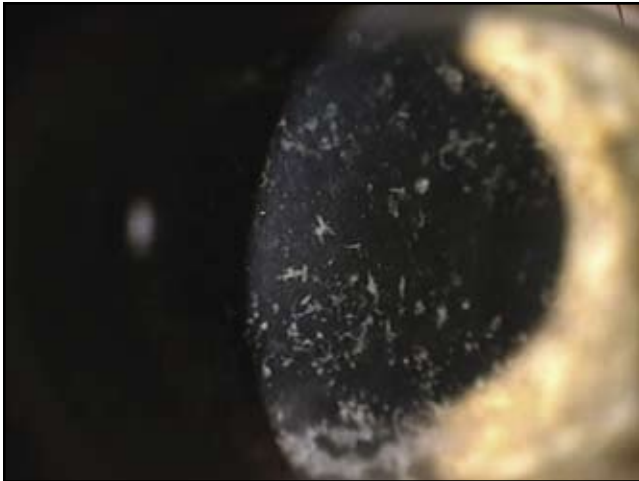

Figure 14-1. Granular dystrophy. (Courtesy of Tracy Swartz, OD, MS.)

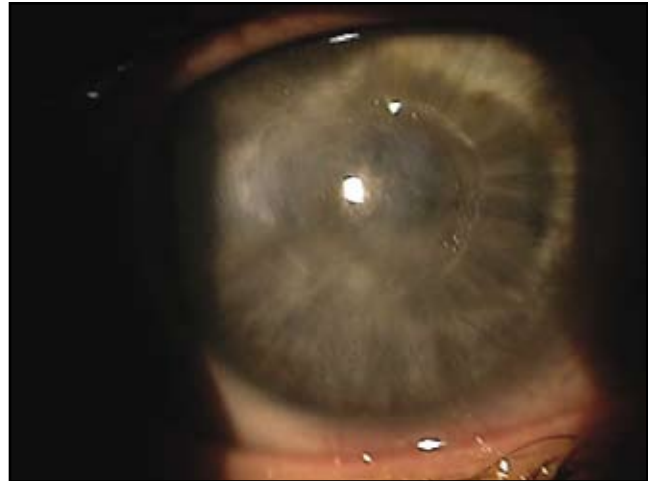

Figure 14-2. Acanthamoeba infection secondary to contact lens wear. (Courtesy of Tracy Swartz, OD, MS.)

PKP is no longer an automatic choice for the surgical treatment for keratoconus; DLK seems to be a safe alternative. Best-corrected visual acuity, refractive results, and complication rates are similar after DLK and PKP. DLK is more technically challenging, but allows the risk of endothelial rejection to be avoided and may reduce the risk of late endothelial failure.^{5,6}

Ramon Naranjo-Tackman, MD, reported first-year results for using the femtosecond laser to cut both the donor and host corneas during the American Society of Cataract and Refractive Surgery 2006 Symposium. Patients showed improved postoperative corneal thicknesses and increased uncorrected visual acuity.⁷

Tectonic support provided by lamellar keratoplasty is also beneficial to eyes that developed keratectasia after LASIK (Figure 14-4). Deep ALK may be a better alternative than PKP for any pathology with healthy endothelium.⁸ An improved visual acuity can be obtained within the first weeks after surgery, and the visual performance of the graft is stable up to 5 years post operation.⁹

Early keratoplasty is more effective than conservative treatment in eyes with corneal alkali burns. Early lamellar keratoplasty after corneal alkali burns can significantly decrease the immune response. Histopathological data also indicate that early lamellar keratoplasty can improve the tissue regeneration and recovery, prevent topical inflammatory reaction, and abate corneal neovascularization.¹⁰

Lamellar keratoplasty with both fresh and dried corneoscleral tissue for treatment of Terrien's marginal degeneration has been shown to be safe and effective.¹¹ Corneal dystrophies, such as macular dystrophy shown in Figure 14-5, affecting the anterior cornea may be better addressed using this technique as well. Microkeratome-assisted lamellar keratoplasty has been found to be a safe and effective method for restoring vision in the treatment of granular corneal dystrophy^{12,13} (see Figure 14-1).

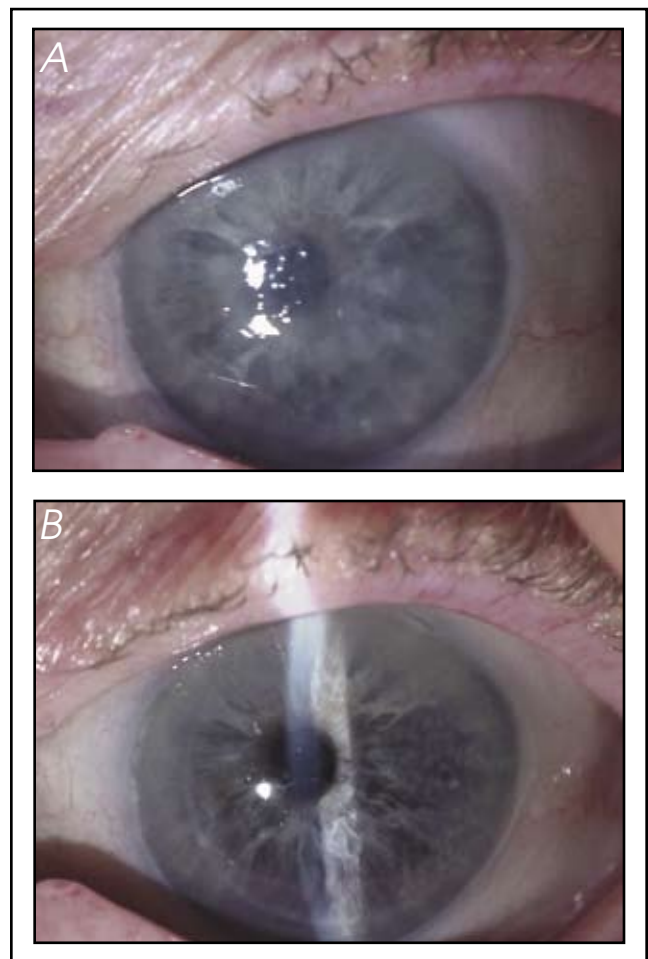


Figure 14-3. (A) Fuchs dystrophy. (B) Postoperative image of the same patient in A who underwent DSAEK for Fuchs dystrophy. (Courtesy of Mark Gorovoy, MD.)

Finally, clinical study of 6 cases of corneconjunctival malignant melanoma suggested the benefit of combining a “no touch technique” with corneoscleral lamellar keratoplasty.¹⁴

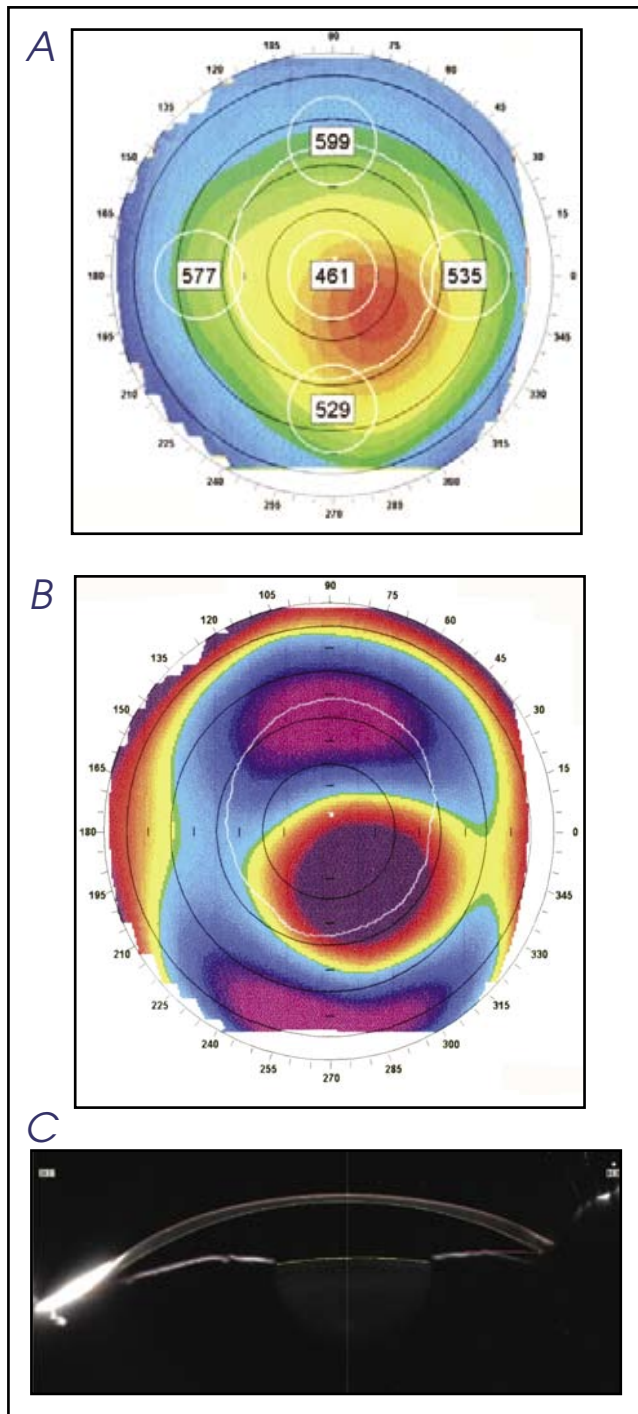


Figure 14-4. (A) Ectasia following LASIK for high myopia with inadequate thickness. (B) Posterior float in the patient in A following LASIK for high myopia. (C) Thin cornea as seen in a Schiempflug image in a patient with ectasia. (Courtesy of Tracy Swartz, OD, MS.)

SURGICAL TECHNIQUE FOR ANTERIOR LAMELLAR KERATOPLASTY

Deep anterior lamellar keratoplasty (DALK) involves dissection of the host cornea to the level of deep stroma,

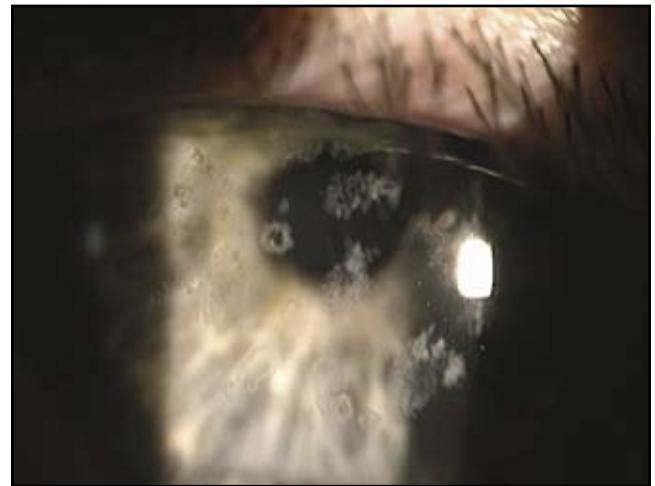


Figure 14-5. Macular dystrophy. (Courtesy of Tracy Swartz, OD, MS.)

followed by transplantation of donor corneal tissue with Descemet's membrane and endothelium. This may be done using several techniques.

The deep stromal pocket approach typically involved manual dissection through a scleral tunnel incision with viscodissection of Descemet's membrane. Visualization of dissection depth during surgery is the most challenging, and an important part of the case. The posterior corneal surface is invisible through an operating microscope. The anterior chamber should be filled with air. The difference in refractive index helps visualize the air-to-endothelium interface. A diamond knife equipped with a micrometer should be used to avoid corneal perforation. Through a 5.0-mm scleral incision, a deep stromal pocket was created across the cornea, using the air-to-endothelium interface as a reference plane for dissection depth. The surgeon wants the tip of the blade to almost touch the air-to-endothelium light-reflex. The pocket is then filled with viscoelastic, and an anterior corneal lamella is excised.

Direct viscodissection of Descemet's membrane from the stroma can be performed by placing a needle into the cornea anterior to Descemet's membrane. When the tip of the needle is slightly anterior to the posterior corneal surface light-reflex, viscoelastic is injected. Descemet's membrane then separates from the overlying posterior stroma. After a corneal pocket filled with viscoelastic was created, approximately 9.0 mm in diameter, a 7.0- or 7.5-mm Hessburg-Barron suction trephine is centered over the anterior corneal surface. The trephine blade is rotated downward until the stromal pocket is entered. The presence of viscoelastic escaping through the incisions indicates entrance into the stromal pocket. Remaining stromal attachments can be cut with a universal corneal scissors, the anterior corneal lamella is removed, and the recipient bed is carefully cleaned¹⁵ (Figure 14-6).

The ability to precisely control flap thickness and diameter reduces the variables permitting a more successful result. Tan and colleagues describes a 2-stage procedure

using the Hanna trephine and a modified automated lamellar therapeutic keratoplasty (ALTK) technique for the treatment of keratoconus. There is no need for any form of manual dissection.^{8,16} Donor lenticules prepared with the ALTK (Moria/Microtek) system can be used in the successful management of eyes requiring tectonic lamellar keratoplasty.¹⁷ The femtosecond laser was used to make the posterior corneal lamellar cuts with relative ease and reliability, thus facilitating the most technically difficult step in this surgery.¹⁸⁻²⁰

Opacification may result in reduced best-corrected visual acuity and contrast sensitivity. The popularity of laser in situ keratomileusis (LASIK) has shown interface opacification to be an abnormality with microkeratome dissection. The microkeratome produces a smoother edge with less surgical trauma compared to manual stromal dissection. Blunt dissections tear stromal lamellae and distort normal corneal architecture.

PREPARATION OF DONOR TISSUE

The posterior surface of the corneoscleral rim is examined. A solution of Trypan blue can be used to stain Descemet's membrane. A sponge will remove the blue stained Descemet's membrane. Corneoscleral rims are mounted epithelial side down onto a punch block, and a 0.25-mm oversized donor button was punched out using a punch trephine.²¹

SUTURING TECHNIQUE

The sutures may be removed at 4 to 6 months after lamellar keratoplasty. Melles suggests that a double running 8-bite 10-0 nylon antitoric suture would be the preferred suturing technique. This suture can be removed at the slit lamp. The depth of the suture is about 90% of the corneal stroma's depth. The donor tissue margins should not protrude anterior to the rim of the recipient bed, to avoid epithelial healing problems.

TOPICAL AND SYSTEMIC THERAPY

I use intraoperative injections with no medicine for the first month, then a tapering dose of topical steroid therapy. The medicine can be tapered quickly because the risk of endothelial allograft rejection is eliminated. In patients with recurrent herpetic keratitis, acyclovir 400 mg 3 times daily should be given for 6 months or more. When indicated, immunosuppressive therapy should be prescribed.

Posterior Lamellar Keratoplasty

Posterior lamellar keratoplasty is a surgical technique used to manage corneal endothelial disorders. The posterior cornea is replaced with a donor button contain-

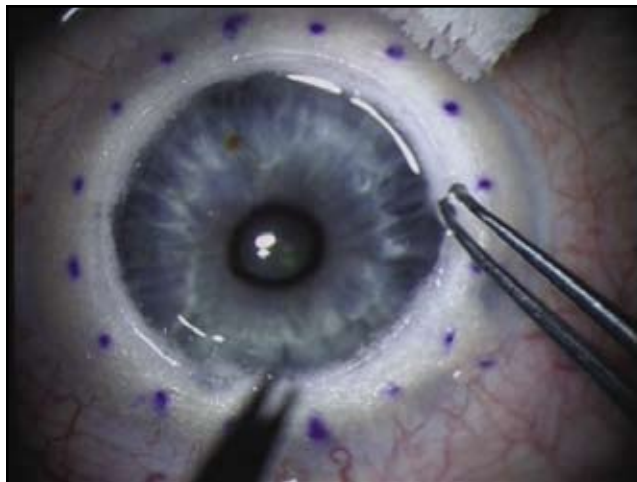

Figure 14-6. A bare Descemet's membrane over a formed anterior chamber following excision of the anterior lamellar. (Courtesy of Mark Terry, MD, and Edwin Chen, MD.)

ing only posterior stroma, Descemet's membrane, and endothelium. It is an effective treatment. An improved visual acuity can be obtained within the first weeks after surgery, and the visual stability of the graft in the long term has been demonstrated. This procedure requires the same stringency of donor tissue as in PKP, because the endothelium is transplanted.²²

Posterior lamellar keratoplasty, there are mainly 2 techniques: microkeratome-assisted posterior lamellar keratoplasty, and posterior lamellar keratoplasty using a deep stromal pocket approach (DLEK, DSAEK; see below). In the first technique, a corneal flap is created using a microkeratome similar to that used in a LASIK procedure. Posterior stroma tissue is then excised by trephination and replaced by a donor disk. The use of the microkeratome in both the host and the recipient results in a much smoother interface between graft and host cornea. A hinged flap adds an element of refractive stability. The anterior lamellar flap is then repositioned to its original place and sutured.

The deep stromal pocket approach has been divided into deep lamellar endothelial keratoplasty (DLEK) and Descemet's stripping lamellar endothelial keratoplasty (DSLEK). DLEK is more labor intensive compared to DSLEK, which does not require manual dissection. A lamellar dissection of the cornea in DLEK starts at the limbus and is technically difficult (Figure 14-7). The femtosecond laser can be used to perform the dissections in the DLEK procedure making this procedure easier and faster. A trephine is used to remove the thin posterior lamella of the dissection including the dysfunctional endothelium. A donor is placed into the recipient bed. The donor is placed in position by an air tamponade. Small-incision DLEK surgery and the lack of corneal sutures preserves the recipient corneal topography, resulting in very little change in astigmatism.²³⁻²⁵

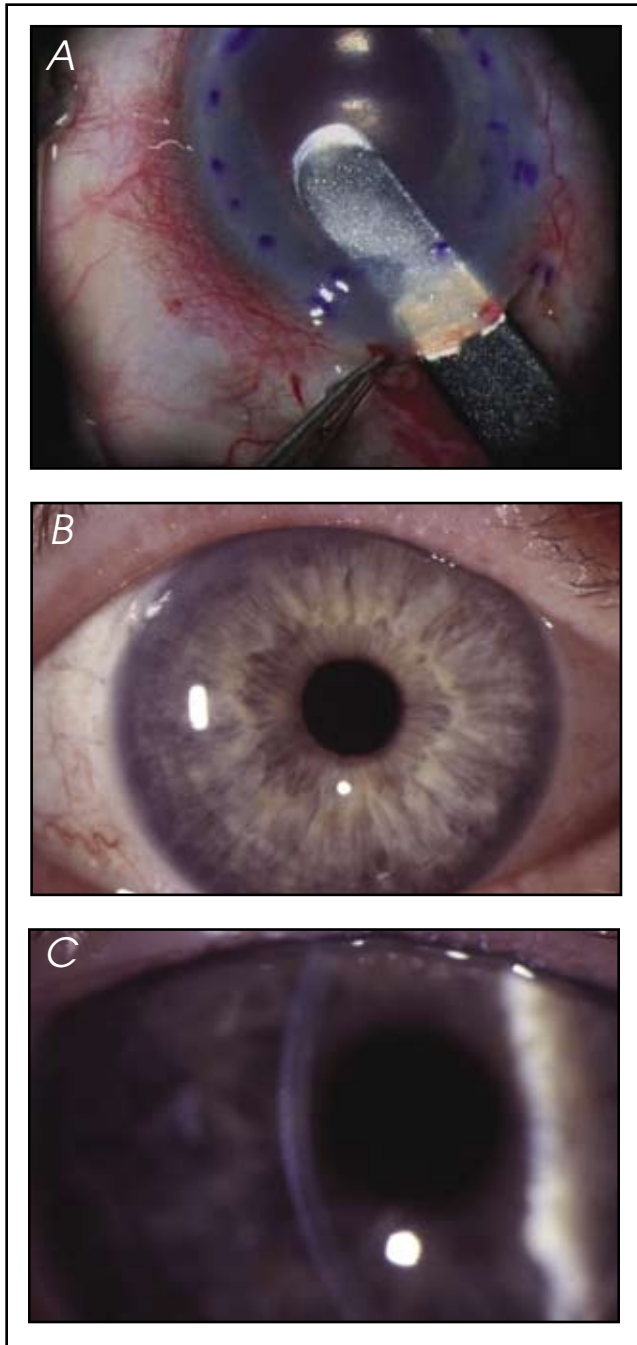


Figure 14-7. (A) DLEK: Intrastromal dissection with Devers dissectors. (B) DLEK: 2 years postoperatively. (C) DLEK: 2 years postoperatively. Note the even posterior surface. (Courtesy of Mark Terry, MD, and Edwin Chen, MD.)

Melles and colleagues perform the posterior lamellar keratoplasty through a 5.0-mm scleral tunnel incision. Descemet's membrane is stripped in a controlled fashion without damaging the posterior corneal stroma to create a recipient stromal bed.²⁶

Descemet's stripping automated endothelial keratoplasty (DSAEK) is a new form of small-incision endothelial transplantation for endothelial dysfunction. The endothelium and Descemet's membrane are stripped

using a scraper (Figure 14-8A). The scraper is used to tear through Descemet's membrane so that the 8-mm circle of Descemet's membrane and unhealthy endothelial cells can be removed.²⁷⁻²⁹

Protective gel is placed on the endothelial side of the DSAEK transplant and then it is folded like a taco. Donor tissue is folded in a 60/40 taco fashion and inserted into the anterior chamber. The tissue is opened so that the donor endothelial cells are oriented to the posterior or backside of the tissue (Figure 14-8B).

The donor corneal lenticule is unfolded in the anterior chamber using a bent 30-gauge needle on a 3-cc air syringe. An air bubble is injected between the folded edges of the donor graft (Figure 14-8C). The tip of the needle can help stabilize the graft. Dislocation of the graft is a well-recognized complication of DSAEK. After the tissue has been unfolded it is positioned to cover the area of the previously stripped Descemet's membrane. Then the anterior chamber is filled with air. An anterior chamber air-fluid infusion is used to tamponade the graft against the host stroma. The limbal incision is closed with sutures (Figure 14-8D and E).

Sutureless microkeratome-assisted posterior lamellar keratoplasty using tissue adhesive may become a new alternative in the surgical treatment of corneal endothelial disorders^{30,31} (Figure 14-9).

Complications and Postoperative Management

Complications of lamellar keratoplasty include detachment of the anterior or posterior lamellar disk, interface opacification that may require future retransplantation, infection, persistent epithelial defect, graft melting, allograft rejection, and descemet membrane detachment.³² Failed grafts may be converted into a PKP.

In DALK, the recipient corneal endothelium showed a small initial drop in endothelial cell density followed by a physiologic rate of cell loss. Cell survival after lamellar keratoplasty may be expected to be better when compared with that following PKP.^{33,34}

Photorefractive Keratectomy for Iatrogenic Ametropia After Deep Lamellar Keratoplasty

Photorefractive keratectomy (PRK) may be used to manage large ametropia or anisometropia following ALK.

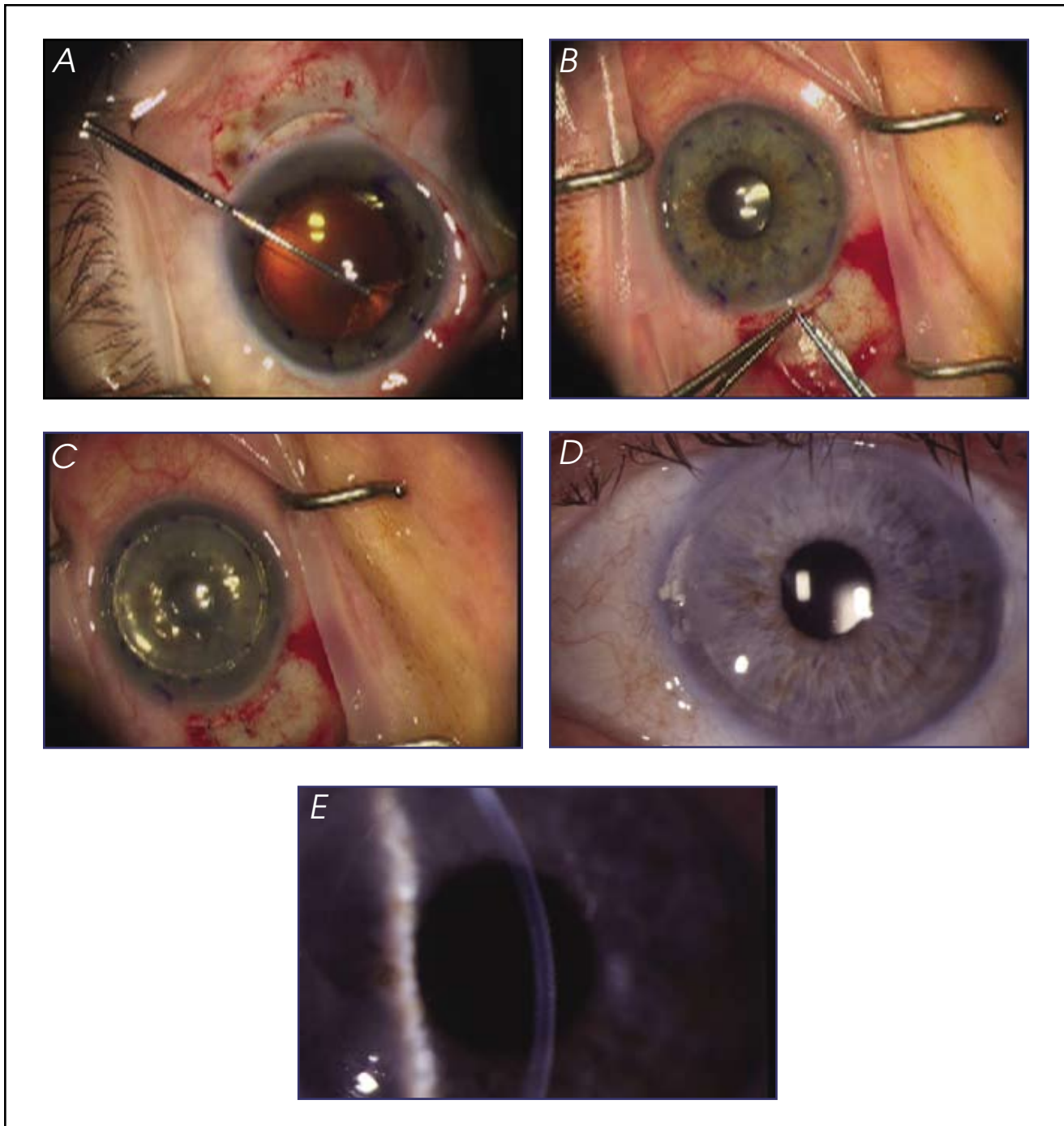


Figure 14-8. (A) DSAEK: Stripping of Decemet's membrane. (B) Insertion of graft. (C) Graft in position with chamber full of air. (D) Six-month postoperative image of a DSAEK patient. (E) Six-month postoperative image of a DSAEK patient. (Courtesy of Mark Terry, MD, and Edwin Chen, MD.)

Pedrotti and colleagues evaluated 9 patients who had irregular astigmatism from 2.0 to 8.0 D following ALK. The mean refractive spherical equivalent changed from -2.98 ± 3.11 D (SD) (range -7.25 to $+3.00$ D) before PRK to -0.58 ± 0.84 D (range 0 to -2.50 D) at the last follow-

up visit. Patients were examined before surgery, and 6, 12, and 24 months after surgery. They concluded customized, transepithelial PRK is a safe and effective treatment for irregular astigmatism after PKP or DLK.³⁵

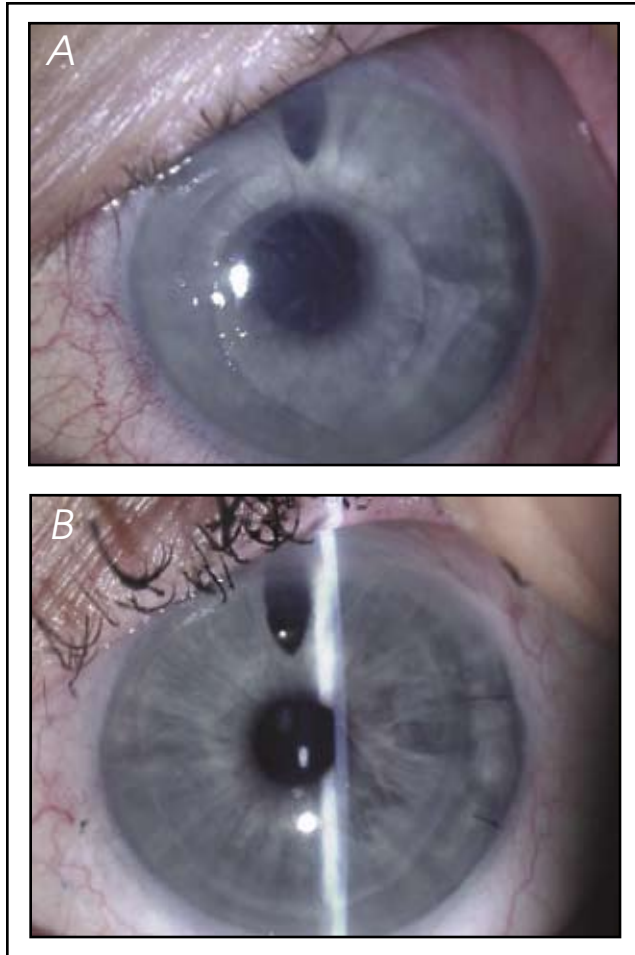


Figure 14-9. (A) Preoperative image of a patient with pseudophakic bullous keratopathy. (B) Postoperative image of patient following DSAEK and relocation of anterior chamber IOL. (A and B, Courtesy of Mark Gorovoy, MD.)

Conclusion

New technologies and new techniques have revolutionized lamellar surgery. Surgeons are able to replace both anterior and posterior corneal pathology. There has been a vast upsurge in the volume of lamellar surgeries to embrace faster and better techniques.

Anterior lamellar surgeries have given the corneal surgeon the ability to manage keratoconus, LASIK-induced kerectasia, corneal alkali burns, Terrien's marginal degeneration, anterior corneal dystrophies, and corneoconjunctival malignant melanoma. Manual and viscoelastic techniques are becoming replaced by the microkeratome and laser. The smoother interface permitted by the microkeratome and the laser will only enhance the patients final best-corrected visual acuity.

Deep anterior lamellar keratoplasty has become a first choice for patients with diseased corneal endothelium. The postoperative visual acuities after DLK showed sur-

prisingly small amount of astigmatism with good refractive results.³⁶ These numbers are comparative to a PKP but the recovery is very different. The technique continues to evolve and evolution of new equipment will make it only more surgery friendly.

References

1. Geerling G, Duncker G, Krumeich J, Melles G. Lamellar keratoplasty. Back to the future? *Ophthalmology*. 2005;102(12):1140-1148, 1150-1151.
2. Bodenmueller MM, Goldblum D, Frueh BE. Retrospective analysis of deep lamellar keratoplasties. *B Klin Monatsbl Augenheilkd*. 2004;221(5):307-310.
3. Muraine M, Toubeau D, Gueudry J, Brasseur G. Impact of new lamellar techniques of keratoplasty on eye bank activity. *Graefes Arch Clin Exp Ophthalmol*. 2007; 245(1):32-38.
4. Tarnawska E, Dobrowolski D, Janiszewska D. Results of posterior lamellar keratoplasty. *Klin Oczna*. 2006;108(4-6):195-198.
5. Watson S, Ramsay A, Dart J, Bunce C, Craig E. Comparison of deep lamellar keratoplasty and penetrating keratoplasty in patients with keratoconus. *Ophthalmology*. 2004;111(9):1676-1682.
6. Paton D. Lamellar keratoplasty. In: *Symposium on Medical and Surgical Disease of the Cornea. Transactions of the New Orleans Academy of Ophthalmology*. St Louis: Mosby-Year Book; 1980;406-427.
7. American Society of Cataract and Refractive Surgery. 2006 Symposium and Congress on Cataract, IOL, and Refractive Surgery March 17-22, 2006, San Francisco, CA.
8. Villarrubia A et al. Deep anterior lamellar keratoplasty in post-laser in situ keratomileusis keratectasia. *J Cataract Refract Surg*. 2007;33(5):773-738.
9. Melles GR, Kamminga N. Techniques for posterior lamellar keratoplasty through a scleral incision. *Ophthalmologie*. 2003; 100(9):689-695.
10. Zheng XF, Feng KX, Li B, Yang JZ, Ge JJ. Effect of lamellar keratoplasty time on the production of serum specific antibody in corneal alkali burns. *Zhonghua Yan Ke Za Zhi*. 2004;40(3):160-164.
11. Yang R Guo R. The treatment of Terrien marginal degeneration using lamellar keratoplasty with dried corneosclera. *Yan Ke Xue Bao*. 2004;20(3):140-143.
12. Hashemi H, Noori J, Zare M, Rahimi F. Microkeratome-assisted posterior lamellar keratoplasty in pseudophakic and aphakic corneal edema. *J Refract Surg*. 2007;23(3):272-278.
13. Chen W, Li GX, Wang QM, Zhao YE, Qu J. Microkeratome-assisted lamellar keratoplasty for recurrent corneal granular dystrophy after phototherapeutic keratectomy. *Zhonghua Yan Ke Za Zhi*. 2005;41(11):1000-1004.
14. Chen J, Sun M, Sha X, et al. Management of corneo-conjunctival malignant melanoma with "no touch technique" surgical excision and corneoscleral lamellar keratoplasty. *Zhonghua Yan Ke Za Zhi*. 2006;42(1):22-26.
15. Melles GRJ, Remeijer L, Geerards AJM, Beekhuis WH. A quick surgical technique for deep lamellar keratoplasty using visco-dissection. *Cornea*. 2000;19:427-432.
16. Tan D Ang L. Modified automated lamellar therapeutic keratoplasty for keratoconus: a new technique. *Cornea*. 2006;25(10):1217-1219.
17. Wiley LA, Joseph MA, Springs CL. Tectonic lamellar keratoplasty utilizing a microkeratome and an artificial anterior chamber system. *Cornea*. 2002;21(7):661-663.
18. Soong HK, Mian S, Abbasi O, Juhasz T. Femtosecond laser-assisted posterior lamellar keratoplasty: initial studies of surgical technique in eye bank eyes. *Ophthalmology*. 2005;112(1):44-49.

19. Sarayba M, Juhasz T, Chuck R, Ignacio, Nguyen T, Sweet P. Femtosecond laser posterior lamellar keratoplasty: a laboratory model. *Cornea*. 2005;24(3):328-333.
20. Mian S, Soong H, Patel S, Ignacio T, Juhasz T. In vivo femtosecond laser-assisted posterior lamellar keratoplasty in rabbits. *Cornea*. 2006;25(10):1205-1209.
21. Melles GRJ, Remeijer L, Geerards AJM, Beekhuis WH. A quick surgical technique for deep, anterior lamellar keratoplasty using visco-dissection. *Cornea*. 2000;19(4):427-432.
22. Melles G, Kamminga N. Posterior lamellar keratoplasty can be an effective surgical technique to manage corneal endothelial disorders. *Ophthalmologe*. 2003;100(9):689-695.
23. Fogla R, Padmanabhan P, Nethralaya S. Initial results of small incision deep lamellar endothelial keratoplasty (DLEK). *Am J Ophthalmol*. 2006;141(2):346-351.
24. Terry MA, Ousley P, Will B. Practical femtosecond laser procedure for DLEK endothelial transplantation: cadaver eye histology and topography. *Cornea*. 2005;24(4):453-459.
25. Terry M, Ousley P. Small-incision deep lamellar endothelial keratoplasty (DLEK): six-month results in the first prospective clinical study. *Cornea*. 2005;24(1):59-65.
26. Melles GR, Wijdh RH, Nieuwendaal CP. A technique to excise the descemet membrane from a recipient cornea (descemetorhexis). *Cornea*. 2004; 23(3):286-288.
27. Groat B, Ying M, Vroman D. In the second approach Descemet-stripping automated endothelial keratoplasty technique in patients with anterior chamber intraocular lenses. *Br J Ophthalmol*. 2007; 91(6):714.
28. Gorovoy M. Descemet-stripping automated endothelial keratoplasty. *Cornea*. 2006;25(8):886-889.
29. Meisler D, Dupps W, Covert D, Koenig S. Use of an air-fluid exchange system to promote graft adhesion during Descemet's stripping automated endothelial keratoplasty. *J Cataract Refract Surg*. 2007;33(5):770-772.
30. Pirouzmanesh A, Herretes S, Reyes J, Suwan-Apichon O, Chuck R, Wang D. Modified microkeratome-assisted posterior lamellar keratoplasty using a tissue adhesive. *Arch Ophthalmol*. 2006; 124(2):210-214.
31. Terry MA, Ousley PJ. Endothelial replacement without surface corneal incisions or sutures. *Cornea*. 2001;20:14-18.
32. Ibrahim M, Tu K, Kaye S. Spontaneous resolution of descemet membrane detachment after deep anterior lamellar keratoplasty. *Cornea*. 2006; 25(1):104-106.
33. Van Dooren B, Mulder P, Nieuwendaal C, Beekhuis W, Melles G. Endothelial cell density after deep anterior lamellar keratoplasty (Melles technique). *Am J Ophthalmol*. 2004;137(3):397-400.
34. Van Dooren B, Mulder P, Nieuwendaal C, Beekhuis W, Melles G. Endothelial cell density after posterior lamellar keratoplasty (Melles techniques): 3 years follow-up. *Am J Ophthalmol*. 2004; 138(2):211-217.
35. Pedrotti E, Sbabo A, Marchini G. Customized transepithelial photorefractive keratectomy for iatrogenic ametropia after penetrating or deep lamellar keratoplasty. *J Cataract Refract Surg*. 2006; 32(8):1288-1291.
36. Yepes N, Segev F. Five-millimeter-incision deep lamellar endothelial keratoplasty: one-year results. *Cornea*. 2007;26(5):530-533.

